Anatomy—The Head and Neck

BY LES SELLNOW

The equine head can be compared to a computer. Housed within the skull are the major "components—the brain and the sense organs. In addition to functioning like a computer, the equine head contains teeth for cropping grass and chewing food, and all of the necessary components for moving the food to the digestive system, as well as housing the respiratory apparatus that allows for air to be inspired and expired.

No matter the conformation of your chosen breed, the heads and necks of horses serve many purposes

Connecting the head to the rest of the body is the neck, which also serves as an important element of balance as well as containing vertebrae and a continuation of tubes for the movement of food, water, air, and blood.

The shape of a horse's head and neck is often the focal point of discussion when equine beauty is the topic. To the Arabian horse fancier, the broad forehead, dished face, ears that tip in, and a tiny muzzle are all attractive components when perched on an arched neck. The draft horse fancier likely could care less for a head that appears to have been sculpted. To that individual a large head that is proportionate with a large

ROBIN PETERSON ILLUSTRATION

Editor's Note

This is the sixth in a 12-part series of articles on equine anatomy and physiology. Future topics include the hoof, the head and neck, the back, muscles, tendons and ligaments, the digestive system, the circulatory and respiratory systems, and the reproductive system.

body and a neck that is muscular and strong are the components being sought.

An anatomically correct horse will have a head that is proportionate to its body size, and the shape will be characteristic of the breed.

There are a couple of other requirements when looking at the ideal equine head. The forehead should be broad and well defined to provide space for wide-set eyes. The lower jaw should also be well defined and with good width between the branches so that there is ample space for the larynx. In addition, the nostrils should be wide and capable of flaring into even larger openings so the horse can increase air intake during exercise. (While that point is widely held by many horse owners, there are those in the scientific community who say there is little or no research data to support the contention that flaring nostrils permit additional intake of air.)

As we explore the anatomy of the equine head and neck, it must be pointed out that the information in this article comes from a wide variety of sources, including textbooks and papers on equine anatomy. However, special attribution must once again be given to *The Coloring Atlas Of The Horse*, authored by former Colorado State University faculty members Thomas O. McCracken, MS, and Robert A. Kainer, DVM, MS.

THE EAR

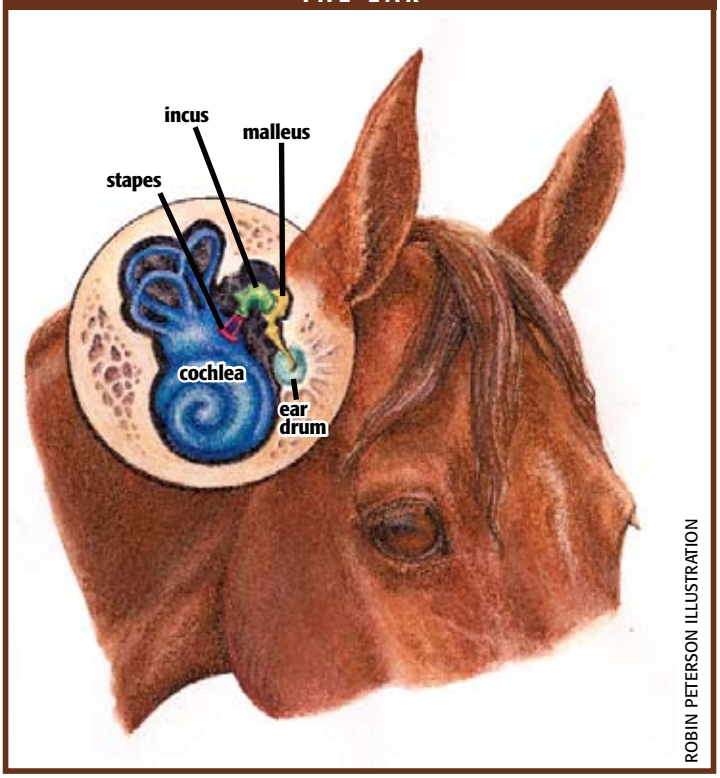

ROBIN PETERSON ILLUSTRATION

Bone Head, With Lots of Air

It might come as a surprise to some horse owners to realize the equine skull is comprised of 34 bones, most of them flat.

During the birthing process, these bones yield and overlap, allowing the skull

to be somewhat compressed and thus allowing for easier parturition. The bones have fibrous joints, which are basically immovable joints where the bones are bound by fibrous tissue that ossifies as the horse matures.

The equine brain is located within a cranial cavity. The cranial cavity is partially divided by a down-growth of the skull roof, with the rostral compartment housing the cerebral hemispheres of the forebrain and the caudal compartment housing the cerebellum of the rear brain. The brain is continuous with the spinal cord. The brain lies in the upper forehead of the horse and, of course, is the key component in this unique "computer."

The respiratory tract starts with the nostrils, which are the openings into the nasal cavity. The perpendicular partition separating the nasal cavity into left and right halves is known as the median nasal septum. It is composed of bony, cartilaginous, and membranous parts.

Structures within the nasal cavity include the turbinate bones, also known as nasal conchae. They contain mucous-secreting epithelium that functions as something of an air conditioning process as it warms, moisturizes, and filters inspired air. The nasal conchae and the median nasal septum divide the nasal cavity into passageways; each passageway is called a meatus.

The largest of these passageways is known as the ventral nasal meatus and leads directly into the nasophaynx. The pharynx is a passageway, comprised of muscle and membranous tissue, that is located between the mouth-nostrils area and the larynx and esophagus. The portion of the pharynx above the level of the soft palate is the nasopharynx.

The larynx is the upper end of the trachea or windpipe. It is a tubular structure comprised of muscle and cartilage that contains the vocal cords and connects the nasopharynx with the trachea. The trachea is a cartilaginous and membranous tube descending from the larynx and branching into the right and left bronchi.

The roof of the mouth is formed from the hard palate in front and the soft palate close behind and continuous with it.

In technical terms, with an assist from the above-mentioned authors, here is how

HEAD AND NECK

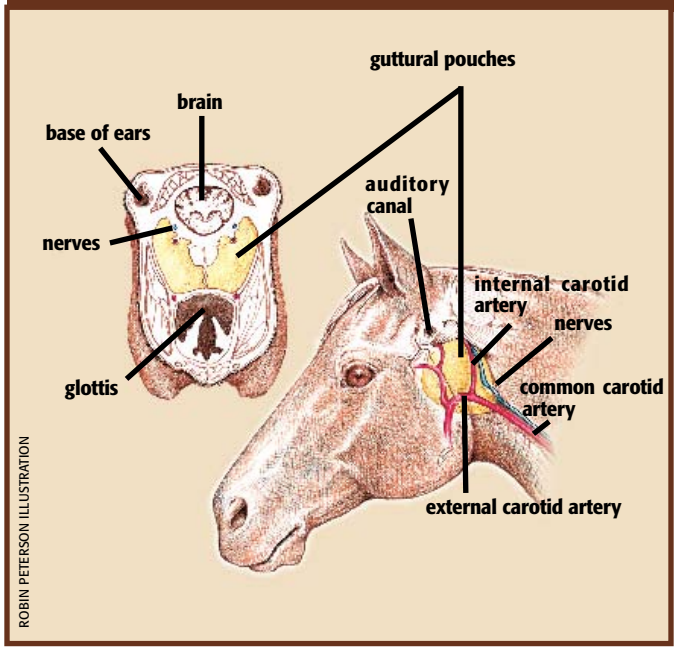

ROBIN PETERSON ILLUSTRATION

the apparatus functions:

When the horse is breathing, the free edge of the soft palate is usually under the epiglottis and the laryngeal entrance is open. During swallowing, muscles raise the tongue, pressing food or water against the hard palate. The root of the tongue is pulled rearward, the laryngeal entrance is narrowed, and the soft palate is elevated to the caudal wall of the pharynx. Increased pressure in the pharynx forces feed or water into the esophagus where involuntary contractions cause it to journey on to the stomach.

What this all means in simple terms is that during the breathing process, the pharynx and soft palate form a smooth, uninterrupted passageway for the flow of air into the trachea. When the horse swallows, the pharynx and soft palate move so that food is directed into the esophagus rather than the trachea. There can be a variety of afflictions capable of altering the soft palate, causing caudal displacement and preventing its return to the normal breathing position.

Lending a major assist in preventing food from being inspired into the lungs is the epiglottis, a lid-like structure overhanging the entrance to the larynx. Its job is to close the laryngeal opening when the horse swallows, thus making certain that food and water head down the esophagus and into the stomach instead of winding up in the trachea and the lungs.

The horse's tongue lies on the floor of the mouth and is composed of a mass of muscle anchored by the hyoid bone and the bodies of the left and right mandibles—lower jaw.

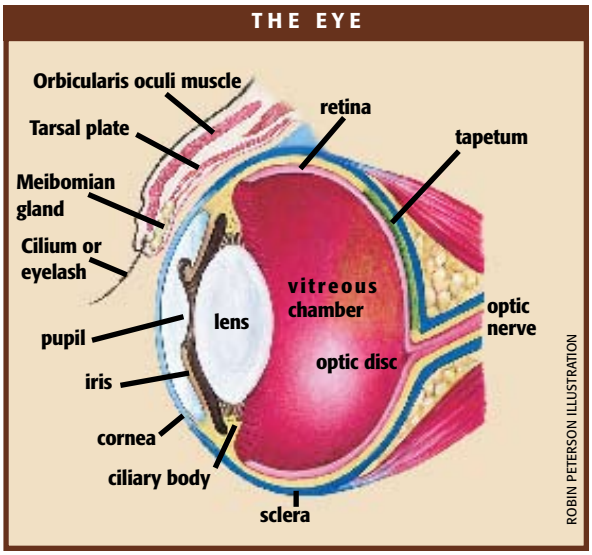

Something To Chew On

One of the skull's most important components involves the teeth. They are used for cropping grass and grinding food as part of the masticating process. When a foal is born, it is generally toothless, but very soon it will have a full set of baby teeth (24). They are divided into six upper and six lower incisors and six upper and six lower molars, and they are replaced with adult teeth around age three.

The adult male horse has six upper and six lower incisors; six upper and six lower

pre-molars (the most forward set of cheek teeth); six upper and six lower molars (the cheek teeth at the rear of the mouth); two upper and two lower canine teeth; and two wolf teeth located adjacent to the premolars in the horse's upper jaw.

The incisors are used for cropping grass and the molars for grinding it in preparation for the digestive process. Aiding the cause are salivary glands that, in the adult horse, can produce as much as 10 gallons of saliva per day.

Adult females normally have the same complement of teeth as the males, minus the canine teeth.

The tooth of the horse is described as being hypsodont. Simply put, this means the teeth are constantly erupting as the grinding action of eating wears away the crown surface. One can compare it to chalk being used on a blackboard. After a time, the chalk becomes so short as to be worthless. It is basically the same with the horse's teeth.

Perhaps one of the most improved areas of equine health care involves dental procedures. Research has shown when teeth are properly cared for, it allows the horse to masticate its food better and, as a result, make better use of the nutrients being ingested.

In the past, many horse owners paid little attention to their horses' teeth, believing that it was best left in the hands of nature. That is no longer case in much of the equine world today, and modern-day horses are healthier because of it.

The Better to See and Hear You...

There are some aspects of equine anatomy that have similarities to human anatomy; the eye is not one of them. The most basic difference stems from the fact that humans are predators and horses are prey animals. Thus, the eyes of humans are close together and can focus quickly on objects both near and far. Looking at objects to right or left involves turning the head in that direction. Human eyes are more comparable to the eyes of cats and dogs than horses.

As a prey animal, the horse has developed both monocular and binocular vision. This means that the horse can see an image with both eyes—binocular—or with one eye only—monocular. Humans have binocular vision only. With monocular vision, the brain often is receiving different messages from each of its eyes.

Important to the good health of equine eyes are the lacrimal glands located just above the eye. Tears secreted by the lacrimal glands wash over the eye and make their way downward, ultimately exiting through the nasal opening.

A horse's hearing is more acute than that of a human as its uniquely shaped ears funnel sounds to the brain. In a September 2005 article in *The Horse* (www.TheHorse.com/emag.aspx?id=6016), the writer noted that horses' ears are finely tuned instruments designed to convert sound waves in the environment into action potentials in the auditory nerve. This nerve, which is located at the base of the skull, sends information to the brain to be translated and interpreted.

The horse uses his pinna (the large, cup-like part of the ear that you can see) to collect sound waves from the environment. Made of cartilage, the pinna can rotate to capture sound waves from all directions because horses have 16 auricular muscles controlling their pinna. After being trapped by the pinna, the collected sound waves are funneled through the external ear canal (commonly referred to as the auditory canal) to the middle ear, where they cause the eardrum, a thin membrane, to vibrate.

These vibrations are sent through the ossicles, a series of three tiny bones called the malleus, incus, and stapes. Finally, they reach the inner ear, where they cause vibrations in a snail-shaped structure called the cochlea.

Running up and down the cochlea are extremely sensitive hair cells that act as transducers. When these hair cells bend, they generate electrical signals that stimulate the auditory nerve. This nerve passes the impulses to the brain.

A Pouch for Trouble

Before leaving the skull, we must call attention to a component that is unique to the horse—guttural pouches. There is a guttural pouch on either side of the horse's head, and each is divided into a larger inner and small outer compartment. The guttural pouch is a grapefruit-sized sac that is interposed in the eustachian tube that connects the middle ear with the nasal passage.

The normal guttural pouch can be described as an air-filled sac. However, while the image of a balloon comes to mind, the normal guttural pouch is not distended with air, as is the case with an inflated balloon.

Why nature provided equids—and no other mammals—with guttural pouches is a mystery, with some scientists thinking the pouches might have something to do with balance. One thing is certain, when there is a fungal attack in the guttural pouch, it can be a serious health problem.

Along the Neck

As mentioned earlier, the shape of a horse's neck can be involved in what one considers attractive or unattractive conformation, but that sometimes has little to do with function. A short, cresty neck is undesirable because it can inhibit proper function. If the thickness extends all the way into the throatlatch, it can cause problems. Both the trachea and the esophagus enter the neck at that point—as do a vital network of veins and arteries that convey the blood supply to and from the brain. When a horse with a thick throatlatch is asked to "set its head" or carry its head in a perpendicular frame, these vital passageways often are constricted.

A short, heavy neck also restricts the use of the neck and head as balancing mechanisms.

One of the methods utilized in determining optimum neck conformation is to measure the top and bottom of the neck. The top runs from the poll to the withers, and the bottom runs from the throatlatch to the neck-shoulder junction. The proper ratio in the minds of many is two to one, top to bottom.

There are seven cervical vertebrae in the horse's neck, with the spinal cord exiting the brain and running through them. The vertebrae are connected via cartilaginous joints. These joints are slightly movable and are united by connective tissue. Problems that develop within, or to, the cervical vertebrae can mean serious problems.

There is a correlation between the length of the cervical vertebrae and the length of the neck—the longer the individual vertebrae, the longer the neck.

The vertebrae of the neck connect with the vertebral column of the back, which we will be discussing next month.

ABOUT THE AUTHOR

***Les Sellnow** is a free-lance writer based near Riverton, Wyo. He specializes in articles on equine research, and he operates a ranch where he raises horses and livestock. He has authored several fiction and non-fiction books, including* Understanding Equine Lameness, Understanding The Young Horse, *and* The Journey of the Western Horse, *published by Eclipse Press and available at www.ExclusivelyEquine.com or by calling 800/582-5604.*